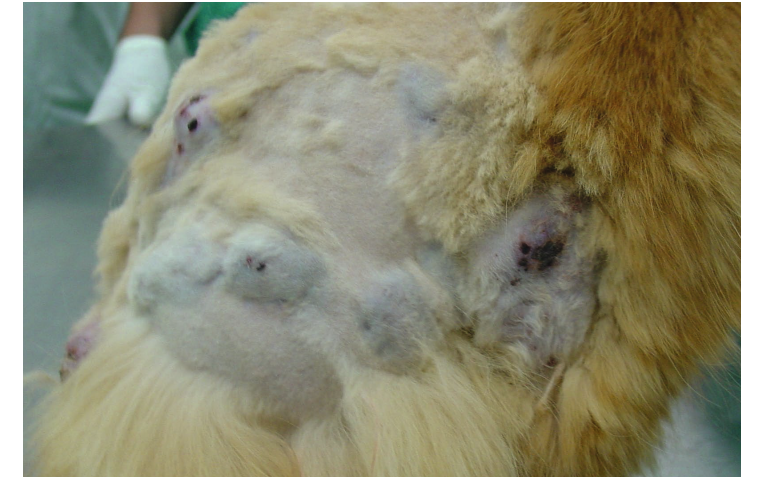
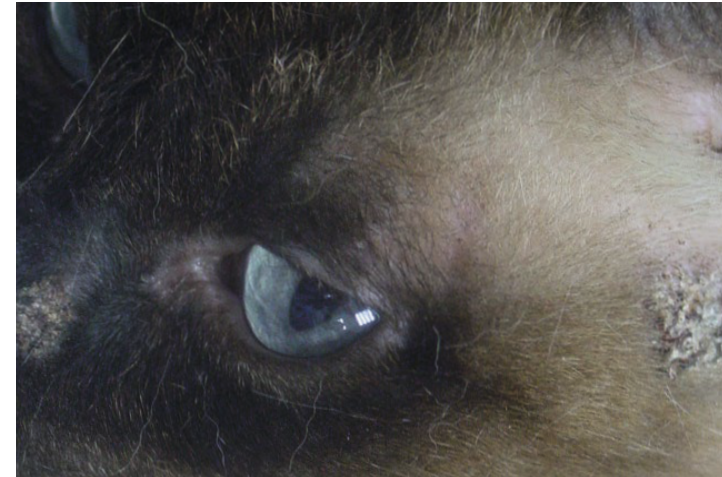
DIAGNOSING DERMATOPHYTOSIS

Dr Carmen Lorente, DVM, PhD, DipECVD. EBVS® European Specialist in Veterinary Dermatology

Dermatophytosis is a fungal skin disease commonly caused by *Microsporum canis*, *M. gypseum* and *Trichophyton spp.* The condition is contagious and a potential zoonosis.



Clinical picture: focal or multifocal alopecia, crusting lesions.

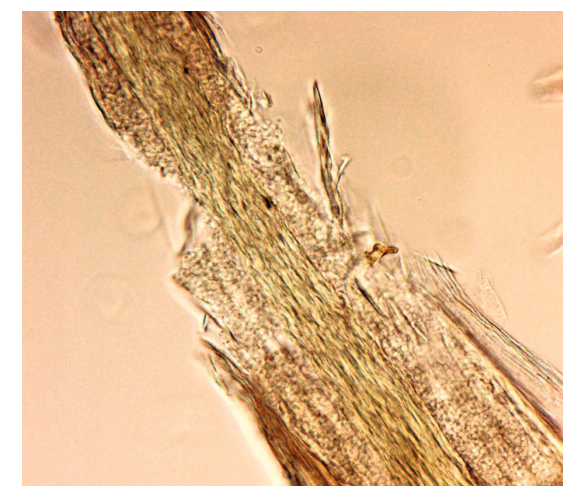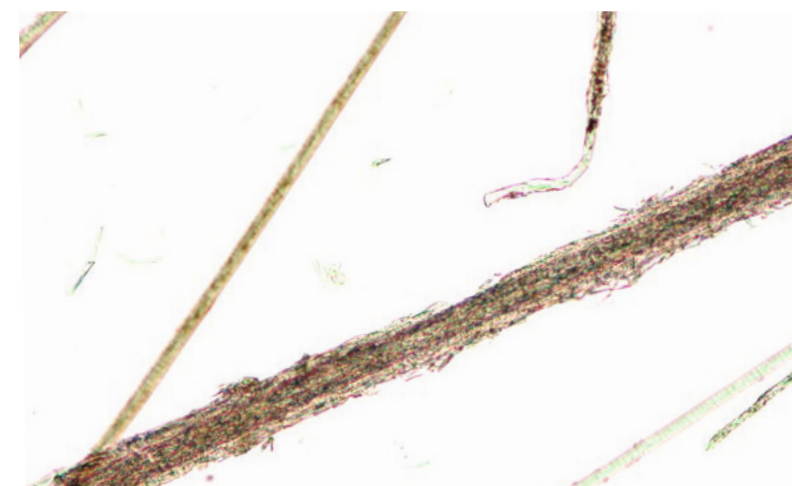Nodular lesions: dermatophytic kerion (dogs) / Dermatophytic pseudomycetoma (cats).

1. DIAGNOSTIC TOOLS GUIDANCE



Wood's lamp

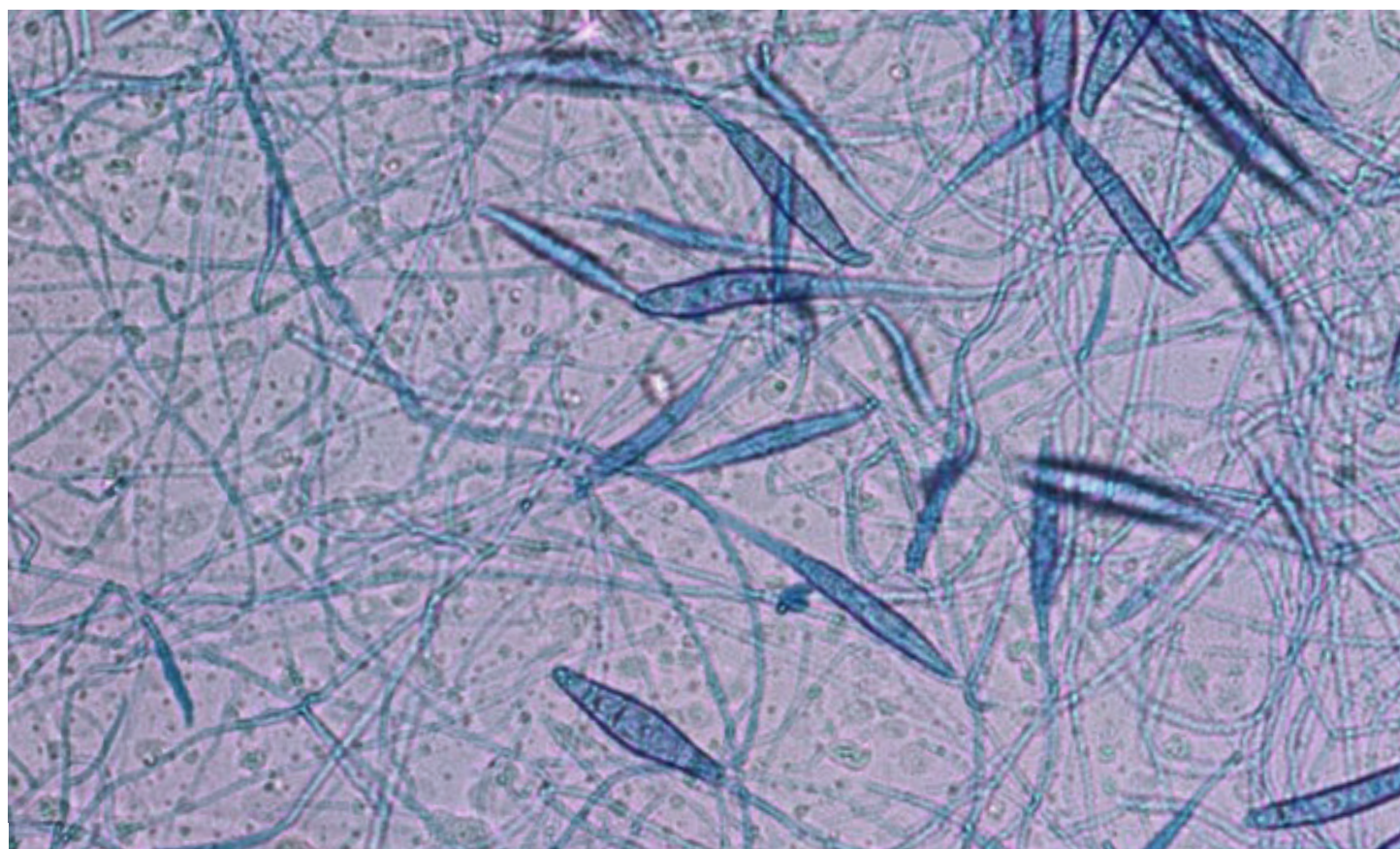
Most *M. canis*-infected hair shafts produce a characteristic green fluorescence under Wood's lamp. Useful to identify hairs to sample for trichography, culture and PCR. Very interesting to monitor the response to the treatment.



Trichography

Sample hairs with green fluorescence or plucked from the periphery of the lesion. The hairs lose their structure and break. Spores can be seen around the infected hairs and hyphae inside the hair shaft.

2. RECOMMENDED DEFINITIVE DIAGNOSTIC TESTS



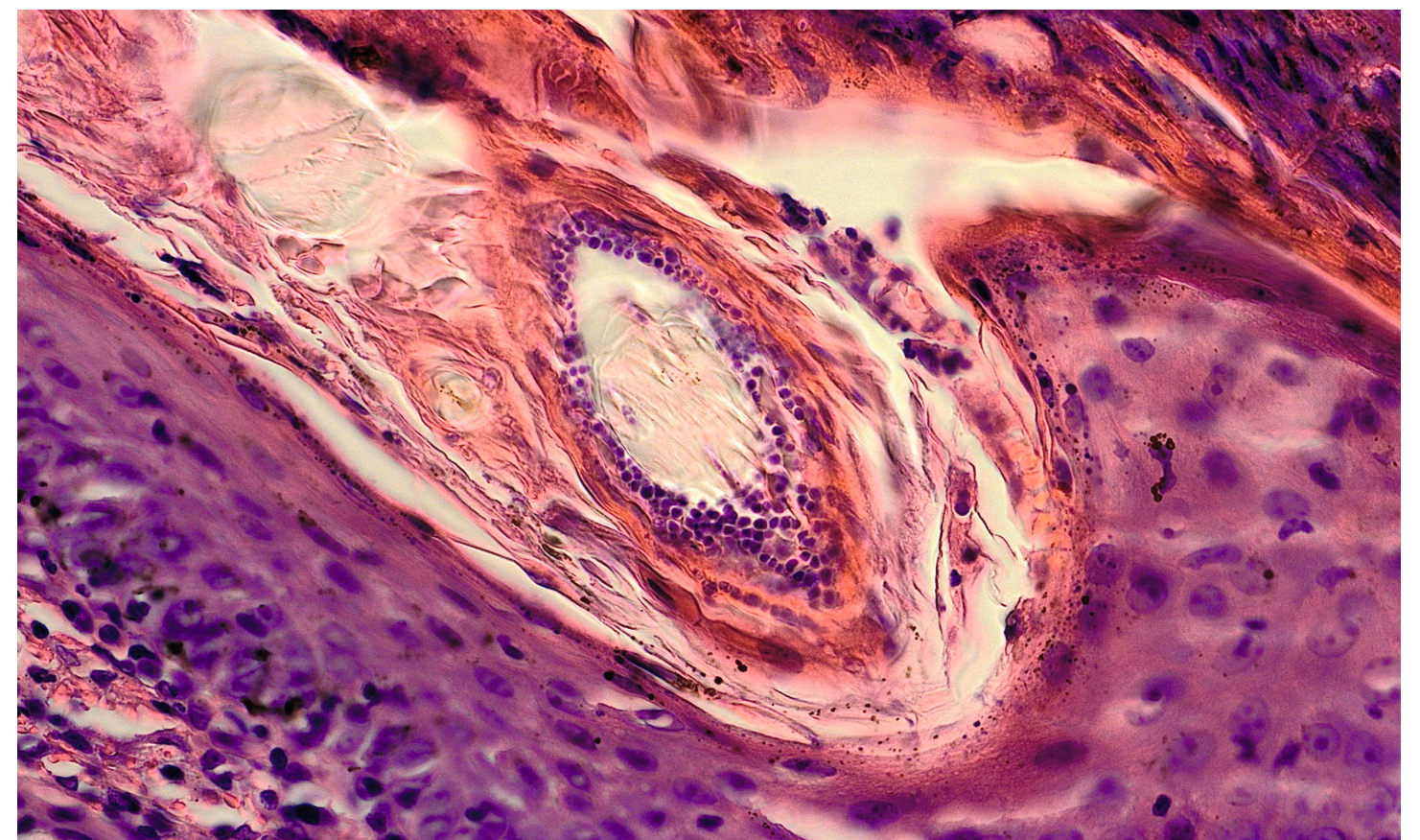
Dermatophyte culture

Sampling techniques: hair coat brushings, hair plucking and Scotch tape sampling. False positives and negatives can occur due to the sampling technique, and interpretation of the growth. Dermatophyte growth changes the Dermatophyte Test Medium (DTM) colour in less than 24h. A wide range of contaminants can also cause a red colour change in the medium. The dermatophyte always must be identified based on the morphology of the colony and of the macroconidia. It is recommended to carry this out in a specialised laboratory.

PCR

A positive PCR test can be the result of active infection, fomite carriage or nonviable fungal organisms from a successfully treated infection. A false-negative test can occur because of the sampling technique.

3. OTHER DIAGNOSTIC TEST



Skin biopsy is not a routine diagnostic test, although it can diagnose an active dermatophyte infection. Skin biopsy is required for diagnosing unusual skin lesions such as nonhealing wounds or nodules (Kerion, dermatophyte pseudomycetomas, pustular dermatophytosis) caused by dermatophytosis.

4. TREATMENT

Aims to shorten the course of the disease and prevent spread to other animals and people.

- Systemic Itraconazole (non-compounded) and terbinafine are the most effective and safe treatments for dermatophytosis.
- Topical treatment reduces the spread of spores in the environment. Twice weekly application of lime sulfur, enilconazole or a miconazole/chlorhexidine shampoo.